



Image-guided catheter-based ultrasound thermal ablation of intramuscular and retroperitoneal sarcomas in the transgenic Oncopig cancer model

Laurie A Rund, Goutam Ghoshal, Emery Williams, Paul Neubauer, Lance Frith, Patrick Roady, Lawrence B Schook, E Clif Burdette



Introduction

- Soft-tissue sarcomas (STS) are aggressive, often lethal mesenchymal tumors which have only a 50% 5 year survival rate. This has not changed for decades which highlights the need for more effective therapies.
- Few models exist that can truly simulate size or scale comparable to a human patient and tumors, which are suitable for device technical evaluation.
- This study utilized the Oncopig cancer model (OCM) which was developed to support a broad range of solid tumors following Cre recombinase induced expression of KRASG12D and TP53R167H transgenes.
- Soft tissue sarcomas can be induced by AdCre injection at intramuscular, subcutaneous and retroperitoneal sites within 2 weeks post injection.
- Previous comparison of oncopig and human STS expression profiles using RNA-seq demonstrated that the oncopig soft tissue sarcomas mimic human STS transcription profiles.
- Due to their similar size and anatomy with humans, pigs represent ideal human disease models for development of instrumentation and treatment modalities directly translatable to human medicine.
- The purpose of the present study was to assess the treatment efficacy of 3D spatially-registered real-time image-guided needle/catheter based ultrasound (CBUS) thermal therapy in an induced tumor grown in genetically engineered oncogenic pigs, specifically soft tissue sarcomas of the extremity and retroperitoneum, two clinically relevant sites closely simulating human disease.

Materials and Methods

- Oncopigs 5-8 weeks of age were sedated and injected with varying doses of AdCre (Ad5CMVCre- eGFP; Gene Transfer Vector Core, University of Iowa) as previously described [<https://doi.org/10.1371/journal.pone.0128864>]. Post injection, ultrasound imaging was used to measure tumor growth (SonixTouch (Ultrasonix, Richmond, BC, Canada) a FDA approved clinical ultrasound system with an L14-5/38 GPS probe Tumor length and width were measured with the transducer probe oriented along both the longitudinal and transverse axes. [Fig 1-3]
- Following tumor growth, the pig was anesthetized; ablation treatment utilized 3D image guidance to precisely place the applicator into the tumor through a small (<1 cm) incision; [Fig 4-6]
- Preliminary acute studies involve immediate tissue collection, TCC staining, imaging and fixation for later histologic analysis by a pathologist.
- Recovery experiments were then performed as described above utilizing parameters identified in the acute studies; However, animals were recovered and the treatment zones followed by ultrasound evaluation for up to 12 weeks at which time tissues were collected.

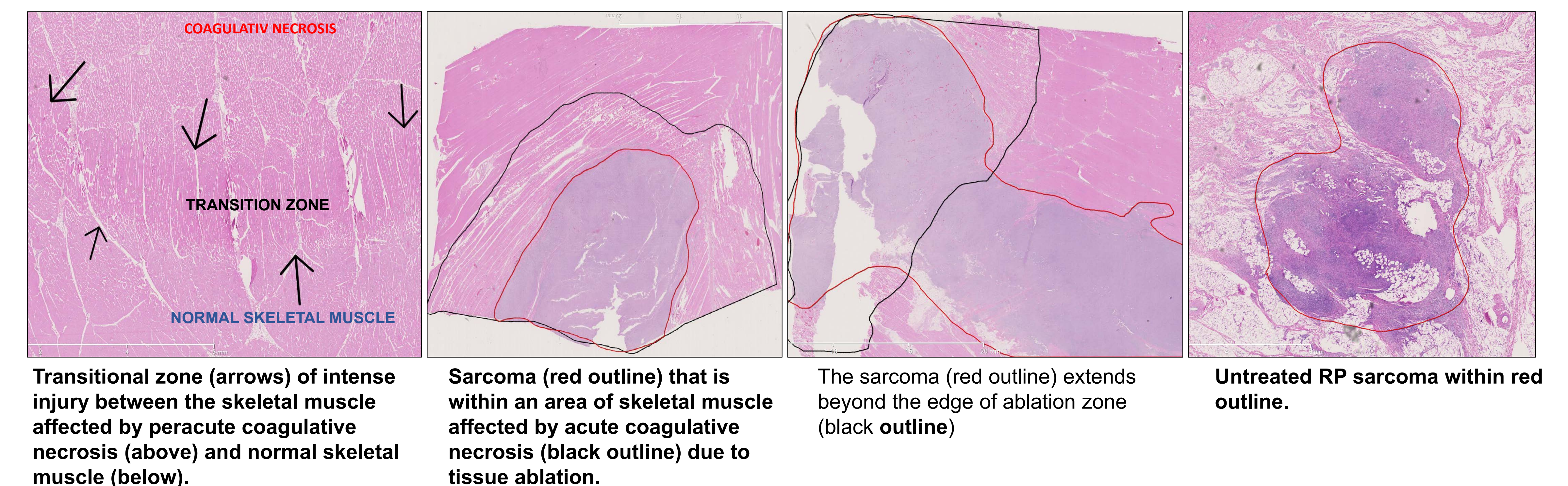
Results - Acute

Table 1. Tumor incidence and volume (cm³) at Day 14 Post Injection for 3 AdCre doses

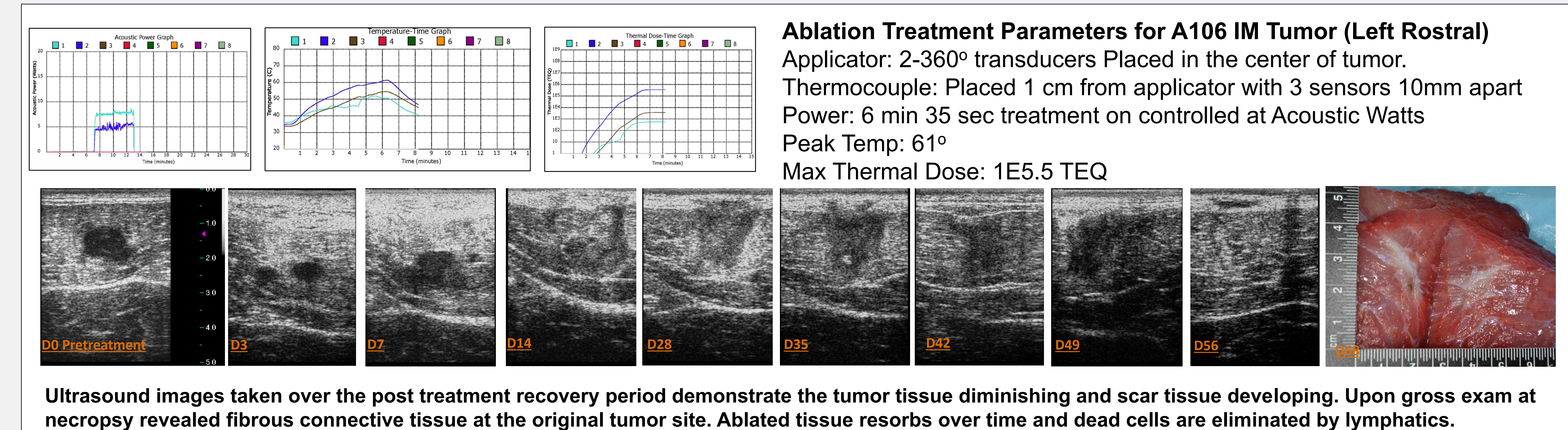
AdCre Dose	SQ Tumor		IM Tumor		RP Tumor	
	Incidence	Volume (D14)	Incidence	Volume (D14)	Incidence	Volume (D14)
2.5x10 ⁸	50%	0.02	75%	1.24±0.86		
5.0x10 ⁸	75%	0.30±0.28	100%	0.85±0.3	100%	47.5±3.5
1.0x10 ⁹	75%	0.35±0.28	100%	0.77±0.34		

Table 2. Treatment statistics – tumor volume ablation volume and thermal dose

	AdCre Dose	Mean Vol Pre-Tx	Post-HITU Ablation Vol	Mean Peak Temp (°C)	Mean Peak Thermal Dose
IM Tumors	5.0x10 ⁸ -1.0x10 ⁹	25.12	43.41	64.56	3.70E+08
RP Tumors	5.0x10 ⁸ -1.0x10 ⁹	19.76	22.87	58.75	1.46E+06



Results - Recovery



Conclusions and Future Work

- Intramuscular (IM) and retroperitoneal (RP) tumors were successfully grown in transgenic oncogenic pigs
- The EM-tracked 3D image guided ultrasound allowed us to target the tumor and deliver interventional controlled high-intensity therapeutic ultrasound (HITU) directly to the tumor, resulting in ablation of the entire tumor volume with a well-defined circumscribed margin.
- First time that a precision HITU interventional device and actually treat a real tumor in a well-characterized large animal model, the oncopig.
- Post treatment monitoring revealed that ablated areas readily healed without complications or recurring tumor development.
- Histologic analysis of treated sites at various recovery time points is underway.

1. Acoustx Applicators

